

Anatomo-Clinical Atlases in SubThalamic Deep Brain Stimulation : correlating clinical data and electrode contacts coordinates

Florent Lalys, Claire Haegelen, Maroua Mehri, Pierre Jannin

► **To cite this version:**

Florent Lalys, Claire Haegelen, Maroua Mehri, Pierre Jannin. Anatomo-Clinical Atlases in SubThalamic Deep Brain Stimulation : correlating clinical data and electrode contacts coordinates. Troisième réunion annuelle de l'ITMO Technologies pour la Santé, Oct 2011, Tours, France. 2011. hal-01237252

HAL Id: hal-01237252

<https://hal.inria.fr/hal-01237252>

Submitted on 3 Dec 2015

HAL is a multi-disciplinary open access archive for the deposit and dissemination of scientific research documents, whether they are published or not. The documents may come from teaching and research institutions in France or abroad, or from public or private research centers.

L'archive ouverte pluridisciplinaire **HAL**, est destinée au dépôt et à la diffusion de documents scientifiques de niveau recherche, publiés ou non, émanant des établissements d'enseignement et de recherche français ou étrangers, des laboratoires publics ou privés.

Anatomo-Clinical Atlases in SubThalamic Deep Brain Stimulation: correlating clinical data and electrode contacts coordinates

Florent Lalys¹, Claire Haegelen^{1,2}, Maroua Mehri, Pierre Jannin¹

¹ Equipe MOST, U746, INSERM-IRISA-INRIA-CNRS, Rennes, France; ² Department of Neurosurgery, Pontchaillou Hospital, Rennes, France

Introduction


- Constructing **digital atlases** gathering location of electrode contacts and clinical scores for a population of PD patients
- Finding the **optimal therapeutic site** for SubThalamic Deep Brain Stimulation (STN DBS) of Parkinson Disease (PD)
- Studying motor improvement and neuro-psychological side-effects

Data

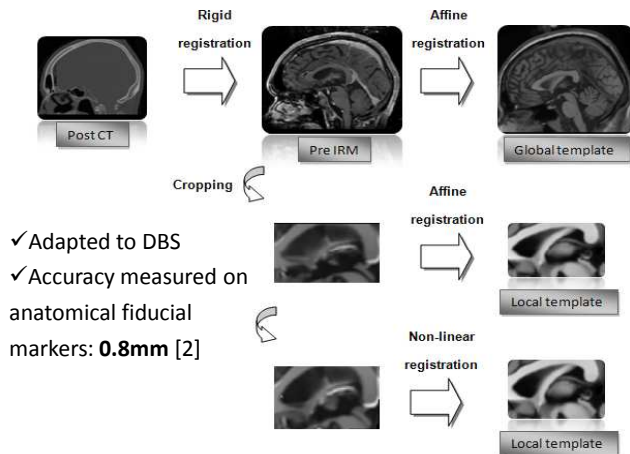
- 30 patients with bilateral STN DBS:
- 15 women and 15 men, mean age: 56 +/- 8 years
 - Pre-operative 3T T1 MRI, pre- and post-operative CT
 - Clinical scores: Pre-op Vs post-op under stimulation
 - Motor scores: UPDRS III, Schwab & England, Hoehn & Yahr
 - Neuropsychological scores: Categorical verbal fluency, phonemic verbal fluency, Trail Making Test (TMT), MATTIS, STROOP

Image Processing

1) Automatic contacts localization on post-op CT [1]



2) Registration on a same anatomical space



Non Supervised Classification

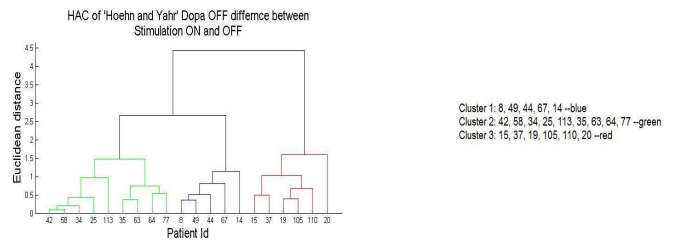
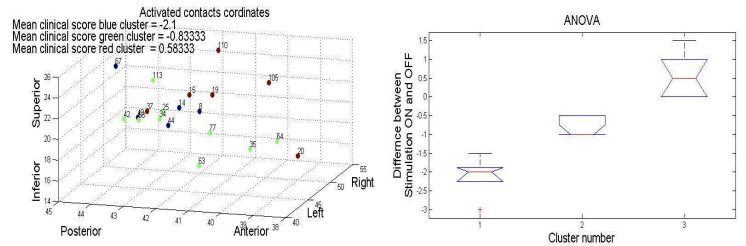
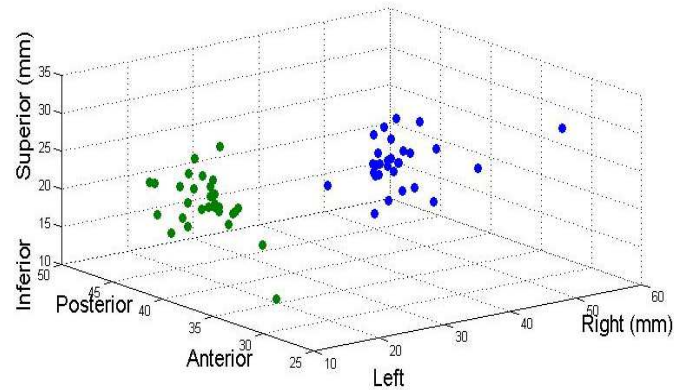
Hierarchical Ascendant Classification (HAC) used on clinical scores merged with coordinates → search homogeneous groups of patients
Vector data: $X = (x, y, z, S)$ with coordinates and clinical score
Ward criterion:

$$d^2(a, b) = \frac{\sum_{k=1}^4 w_k (\bar{x}_{ak} - \bar{x}_{bk})^2}{n_a + n_b}$$

where \bar{x}_a (resp. \bar{x}_b) = $\frac{1}{n_a}$ $\sum_{i=1}^{n_a} x_{ai}$ is the centroid of cluster a (resp. b) and w_k are the weights, specified by $w_1 = w_2 = w_3 = \frac{1}{6}$ and $w_4 = \frac{1}{2}$.

Results

All electrode activated contacts of the 30 patients:
(1 activated contact * 2 electrodes * 30 patients)
Left electrode activated contacts --green
Right electrode activated contacts --blue



UPDRS III: Better improvement in the postero-superior region

Stroop test: Improvement in the postero-superior region and deterioration in the antero-inferior region

Categorical fluency test: Deterioration in the posterior region, improvement in the antero-superior region

Conclusion

Anatomo-clinical atlases are helpful for:

- Better comprehension of phenomenon
- Pre-operative targeting
- Future works will integrate other clinical scores (Quality of life, cognitive criteria)