



**HAL**  
open science

## Needle Insertion in CT Scanner with Image Overlay - Cadaver Studies

Gabor Fichtinger, Anton Deguet, Ken Massamune, Emese Balogh, Gregory Fischer, Hervé Mathieu, Russell Taylor, Laura Fayad, James Zinreich

► **To cite this version:**

Gabor Fichtinger, Anton Deguet, Ken Massamune, Emese Balogh, Gregory Fischer, et al.. Needle Insertion in CT Scanner with Image Overlay - Cadaver Studies. Medical Image Computing and Computer-Assisted Intervention (MICCAI '04), Sep 2004, Saint-Malo, France. pp.795–803, 10.1007/978-3-540-30136-3\_97. inria-00590175

**HAL Id: inria-00590175**

**<https://inria.hal.science/inria-00590175>**

Submitted on 3 May 2011

**HAL** is a multi-disciplinary open access archive for the deposit and dissemination of scientific research documents, whether they are published or not. The documents may come from teaching and research institutions in France or abroad, or from public or private research centers.

L'archive ouverte pluridisciplinaire **HAL**, est destinée au dépôt et à la diffusion de documents scientifiques de niveau recherche, publiés ou non, émanant des établissements d'enseignement et de recherche français ou étrangers, des laboratoires publics ou privés.

# Needle Insertion in CT Scanner with Image Overlay – Cadaver Studies

Gabor Fichtinger<sup>1</sup>, Anton Deguet<sup>1</sup>, Ken Masamune<sup>2</sup>, Emese Balogh<sup>1</sup>, Gregory Fischer<sup>1</sup>, Herve Mathieu<sup>1</sup>, Russell H. Taylor<sup>1</sup>, Laura M. Fayad<sup>1</sup>, S. James Zinreich<sup>1</sup>

<sup>1</sup>Johns Hopkins University, Baltimore, MD, USA

<sup>2</sup>Tokyo Denki University, Japan

email: [gabor@cs.jhu.edu](mailto:gabor@cs.jhu.edu)

**Abstract.** An image overlay system is presented to assist needle placement in conventional CT scanners. The device consisting of a flat LCD display and a half mirror is mounted on the gantry. Looking at the patient through the mirror, the CT image appears to be floating inside the patient with correct size and position, thereby providing the physician with two-dimensional “X-ray vision” to guide needle placement procedures. The physician inserts the needle following the optimal path identified in the CT image that is rendered on the LCD and thereby reflected in the mirror. The system promises to increase needle placement accuracy and also to reduce X-ray dose, patient discomfort, and procedure time by eliminating faulty insertion attempts. We report cadaver experiments in several clinical applications with a clinically applicable device.

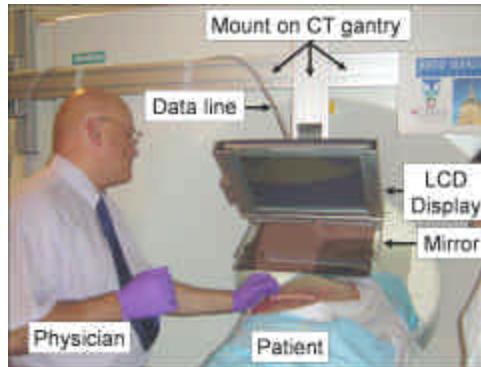
## 1. Introduction

Numerous studies have demonstrated the potential efficacy of CT-guided percutaneous needle-based therapy and biopsy in a wide variety of medical problems. The process of needle insertion is relatively straightforward, but there is significant variability among practitioners, in terms of accuracy and procedure time. Typically, the CT images are shown on the scanner’s console outside the room, and then physician must mentally register the images with the anatomy of the actual patient and use hand-eye coordination to carry out the intervention. To address these problems, a variety of tracked navigation systems and surgical robots have been investigated; all resulting in systems that are prohibitively complex and/or expensive for routine clinical use. A variety of virtual reality methods, such as head-mounted displays [1,2], video projections [3], and volumetric image overlay [4] have been investigated. Unfortunately, all such 3D augmented reality systems, without exception, require elaborate calibration, registration, and spatial tracking of all actors and components; a rather complex and expensive engineering entourage. In the pursuit of simpler image overlay systems, our group [5,6] and concurrently Stetten [7,8] have been investigating 2D image reflection produced in a semitransparent mirror. This technique provides an optically stable 2D reflection image without auxiliary tracking, requiring only a simple pre-operative alignment. As the majority of needle placement procedures are executed “in-plane” (i.e. when the needle is completely contained a single

CT slice), giving up 3D rendering for engineering simplicity and low cost is a most reasonable tradeoff. This paper describes a clinically deployable embodiment of the Masamune-Stetten concept, optimized for needle placement procedures in conventional CT scanners. In particular, we report new hardware, advanced display software, and the results of cadaver studies. Approval is being sought to begin human trials.

## 2. System Design


A flat LCD display and a semi-transparent mirror are mounted on the gantry of a CT scanner (Figure 1). A CT slice is acquired and rendered on the display. The display is positioned with respect to the mirror so that the reflection of the CT image in the mirror coincides with the patient's body behind the mirror (Figure 2), as was



**Fig. 1:** Spinal needle insertion in human cadaver

described in [6]. The overlay is mounted on the gantry, so it tilts with it, if necessary. In many needle placement procedures, after the entry point is selected with using skin fiducial markers, three degrees-of-freedom (DOF) motion of the needle needs to be controlled. The physician uses the overlay image to control the in-plane insertion angle (1<sup>st</sup> DOF), while holding the needle in the axial plane marked by the gantry's laser light (2<sup>nd</sup> DOF). The insertion depth (3<sup>rd</sup> DOF) is marked on the overlay image. In our proof-of-concept prototype [6], the overlay image was created in the imaging plane of the scanner, which allowed for rapid imaging update, but it prohibitively constrained the workspace. The new device uses the outer laser plane of the scanner. While this arrangement provides a conveniently large workspace, it also requires moving the table between imaging and insertion, which is altogether an acceptable trade-off.

The procedural workflow is as follows. The patient is externally marked with IZI CT Biopsy Strip (IZI Corporation, Baltimore, MD). We acquire a CT volume of images, with a slice thickness appropriate for the given application. The plane of insertion is identified and the slice of interest is transferred to the planning and display software running on a Windows-XP laptop. The entry and target points are picked in the CT image, a visual needle guide is displayed, and the scene is pushed to the overlay display as it will be seen later in the left panels of Figure 7. The CT table is translated out by the known offset between the slice of interest and plane of the overlay. The physician places the needle tip at the entry point and lines it up with



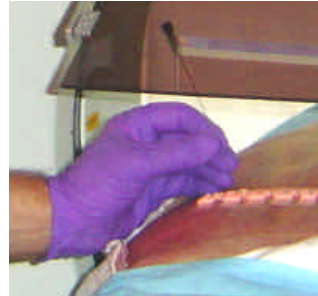**Fig. 2:** Needle insertion in phantom. The CT image appears to be floating inside the body with correct alignment and magnification.

the visual insertion guide seen in the mirror, while holding the needle in the plane of the laser (Figure 1.) The skin fiducials are visible on both the patient and in the overlay image and coincidence between the corresponding marks indicates correct alignment. This feature is particularly useful when the target anatomy is prone to motion due to respiration or mechanical force. (This was not found to be a limiting factor in cadaver studies, however.) Usually, a confirmation image is acquired after insertion, as we show later in Figures 6,7, and 8.


### 3. Display Software and Registration

In the current embodiment, pre-operative calibration, insertion planning, and display image generation are all performed on a stand-alone Windows XP laptop computer. The CT image of interest (containing the target) is transferred from the scanner's distribution server to an ordinary DICOM receiver client running on the laptop. The laptop concurrently drives the flat panel LCD display of the overlay device, for which the image is flipped horizontally so that the mirror would flip the image back to normal lateral polarity. The insertion planning component is kept simple and intuitive, in order to speed up the process. For the sake of simplicity and speed, we refrain from 3D scenes altogether, which is also reasonable for a 2D overlay device. In the interactive display, the physician can select a sub-image of interest, for which the magnification, display, and level can be adjusted. The target and entry points are assigned by two mouse-clicks. A visual needle guide and ruler automatically appear on the screen. The computer flips the scene, and after ensuring correct magnification and orientation, pushes the image to the overlay display. The length of the virtual needle guide is twice the depth of insertion. The physician holds the needle at the entry point behind the mirror and adjusts the height of the grip to match with the proximal end of the virtual needle guide. This posture allows the physician confidently insert the needle with a single stroke along to the marked trajectory, without the risk of overdriving (Figure 3.)

Before use, the display, mirror, and scanner must be aligned. The angle of the display and mirror are fixed with respect to one another and an adjustable arm is used to set up the display-mirror unit with respect to the CT laser. For the in-plane registration a phantom made of a 10 mm thick acrylic board containing a set of 5 mm diameter aluminum pegs is mounted in the overlay plane. A CT image of the pegs is acquired and rendered on the overlay display as seen in Figure 4. The magnification, in-plane rotation, and translation are adjusted until each aluminum peg



**Fig. 3:** Needle insertion with single stroke with the assistance of virtual needle guide



**Fig. 4:** Calibration phantom and its CT image

coincides with its mark in the CT image.

Calibration has a decisive impact on the system's performance; thus this step must be robust to algorithmic and human errors, while still simple and fast. The marks of the aluminum pegs are auto-segmented in the phantom's CT image and then the technician leans over the mirror and selects the points where the pegs appear in the mirror. From these we calculate the in-plane translation and rotation and then correct the overlay image. The combined effects of human and optical errors were analyzed on synthetic data, with the objective to determine the optimal number, distribution, and selection order of registration points. We artificially misaligned the two sets of points (i.e. the pegs and their respective image coordinates) by applying a known transformation on each pair and adding noise to each data point, as explained in Figure 5a. Let  $Q$  and  $R$  be the corresponding points to register in CT and real space. To simulate the error induced by the user and the physical property of the semi-transparent glass, we add some "noise" to the position of  $R$ , obtaining point  $P$ . We register  $P$  to  $Q$  getting a rigid-body transformation  $T_{reg}$ . Using this transformation, we transform  $R$  obtaining  $S$ . Therefore, the system error is the distance between points  $S$  and  $Q$ . Human error was simulated by adding a random value ( $\pm 2$  pixels) to the position of the point to be registered. Parallax error from the mirror may induce a significantly large error. At  $d=4$  mm thickness and  $\alpha=30^\circ$  view angle and using the formulas derived in Figure 5b, the parallax error is about  $x=1.28$  mm, the effect of which fortunately can be substantially reduced by altering the view point during the calibration process. We also concluded that iterative re-registration more favorable than collecting all registration points first and then calculating a single global registration. This observation was true across the range of practically relevant amplitudes and distributions of noise and number of registration points. The best strategy was found to be the following: (1) Pick a peg near the area of interest in the vicinity of expected target and entry. Let the computer calculate translation and readjust the overlay image. (2) Pick a peg far out from the previous one. Let the computer calculate rotation and readjust the overlay image. (3) Pick a new peg again relatively close to area of interest to adjust translation. (4) Pick another peg to adjust rotation, far out and in  $90^\circ$  from the previous one. (5) Repeat the pair-wise process until sufficient registration is observed between the phantom and its CT image. It is particularly important to compensate for the parallax error by altering the viewpoint. The registration error, using four pairs of registration points and assuming  $\pm 2$  pixel human error was 1.23 mm (STD=0.31) at  $30^\circ$  view angle and 0.74 mm (STD=0.21) at perpendicular view ( $\alpha=0^\circ$ ). This performance appears to be sufficiently accurate for most CT-guided needle placement procedures.

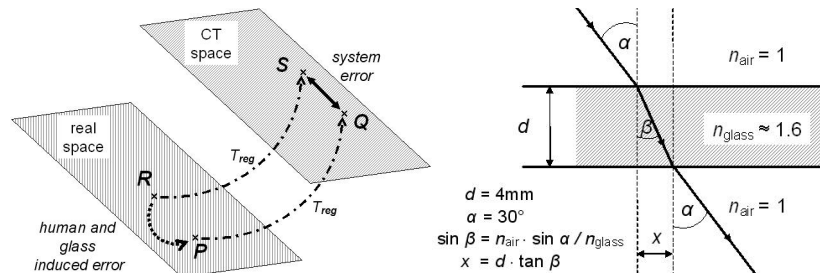


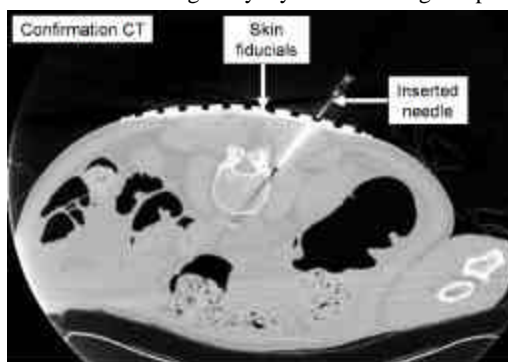
Fig. 5: Definition of registration error (a) and the calculation of parallax error (b)

## 4. Experiments and Results

**Body Phantoms:** A male body phantom was fabricated by attaching three cm-thick tissue-equivalent bolus material (Harpell Associates Inc., Oakville, ON, Canada) on the back of a plastic male torso and placing 1.5 mm diameter metal balls in the bolus at various depths. This phantom represented a male upper body in prone position, with hard fat/muscle layer with mechanical targets in the back, spine, and shoulder. The objectives were to (1) demonstrate accurate needle placement at the pre-marked targets and (2) assess the ergonomics of the system. Experienced and novice interventionalists each executed four needle insertions with 18G diamond needles. The accuracy of needle placement was assessed in post-insertion CT, with 1 mm slice thickness. The experienced and novice users alike approached the implanted targets within 2 mm, in every attempt. The device had excellent ergonomics: there was no interference in the workspace and all targets were conveniently accessible. The ergonomics of the system was also tested on a commercial interventional phantom (CIRS Norfolk, VA) shown in Figure 2, resulting in the same excellent outcome. Also importantly, the reproduction error of the CT gantry mount was consistently below 2 mm (which is less than the width of the laser), tested in 10 trials.

**Cadaver Experiments:** The objective of human cadaver experiments was to demonstrate the ability of precise needle placement to various anatomical targets for a plurality of potential clinical applications. The accuracy of needle placement was assessed in post-insertion CT. The slice thickness was 1.0-3.0 mm, which was clinically adequate for the procedures in our study.

**Spinal Nerve Blocks and Facet Joint Injections** are demanding procedures primarily because of the sheer volume of cases treated regularly by the neurological pain management service at our institution. The interventional team is under strong pressure to perform these procedures in minimum time with clinically sufficient placement accuracy, typically about 2.0 mm. In our experiments, a cadaver was set up in prone position for nerve root and facet joint injections in the lumbar spine area in the setup seen in Figure 1. We performed several needle insertions with standard 22G beveled needles at the L4 and L5. Contrast and therapeutic substances



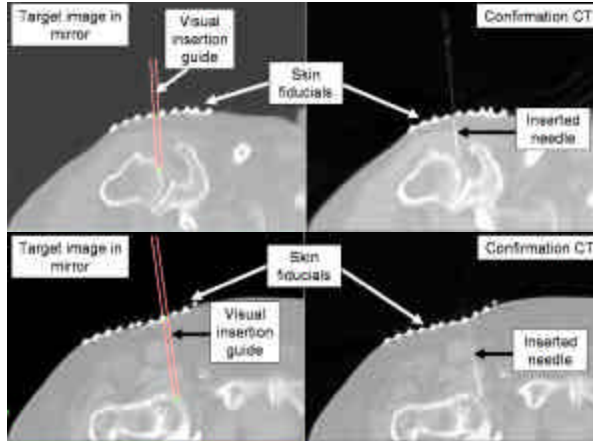
**Fig. 6:** CT of confirmation of needle placement for spinal pain management

were not injected. All four spinal nerve block and facet joint needle placements produced clinically sufficient results. A confirmation CT image is shown in Figure 6, where the needle tip touches the correct anatomical target. The needle is completely included in the confirmation image, indicating the physician managed to keep the needle exactly in the gantry's laser plane.

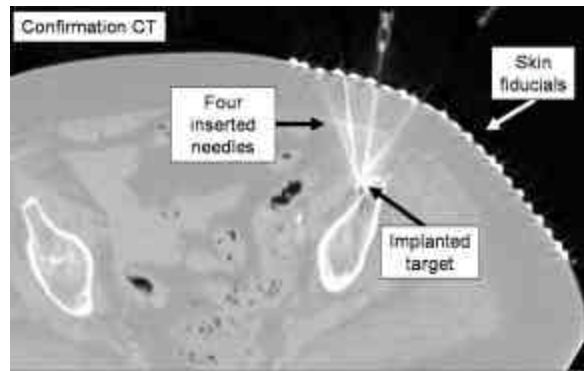
*Shoulder and Hip Arthrographies* are diagnostic procedures frequently applied for assessment of joint injury. Arthrography typically presents a significant scheduling problem, because first an MRI contrast agent is injected percutaneously into the injured joint under CT or X-ray fluoroscopy guidance and then the patient is brought to an MRI imaging facility for diagnostic scanning. We will explore the clinical possibility of joint arthrography with MRI guidance alone. In the anticipation of a forthcoming new MRI-compatible version of the image overlay system, we performed preliminary cadaver studies with CT guidance. In our experiments, we fixed a female cadaver in supine position and performed four needle insertions to the shoulder and hip joint, using standard 22G beveled needles. The accuracy of needle placement

was assessed in intermittent CT and then contrast substance was also injected in two cases. All four needle placements for joint arthrography of the shoulder and hip were clinically successful, two of those shown in Figure 7. Each needle enters the body in the selected entry point, proceeds along the marked trajectory, and touches the selected anatomical target point in the joint space. Contrast material (not shown in the figures) was very hard to inject into the stiffened joint of the cadaver and it did not distribute as evenly as in live patients.

*Pilot Needle for Bone Biopsy:* Bone biopsies are demanding procedures because the needle must make contact with the bone in some predefined angle that is often very difficult to achieve freehand. One must also avoid sensitive structures (like nerves and blood vessels) in the path. As we almost always operate on damaged bone, faulty placement and misalignment of the large needle or drill may cause structural damage to the



**Fig. 7:** Target and confirmation CT for arthrography of shoulder (top) and hip joint (bottom)



**Fig. 8:** Confirmation CT of pilot needle insertion in bone biopsy

already weakened bone; in fact, fracture is not an insignificant intra-operative risk. Many patients have preexisting micro-fractures, a condition that may develop into a full fracture if the instrument is accidentally wedged in the fracture line. Altogether, unassisted freehand planning of the skin entry, trajectory, bone entry, and cortical target can become exceedingly difficult. In our experiments, we fixed a female cadaver in supine position and performed four needle insertions to the pelvis, using standard 22G beveled needles. A 1.0 mm steel ball was implanted percutaneously into the right lateral wall of the left pelvis, and then this location was targeted from several directions from different entry points. All four the pilot needle insertions for pelvic bone biopsy were clinically successful. A confirmation CT is shown in Figure 8. Unfortunately, the artifact caused by the needles suppresses the signal of the implanted metal target, but the needles converge in a confined area, indicating satisfactory accuracy for bone biopsy. Three of the four needles are completely included in the image slice, while the fourth one is slightly deflected from the image plane.

## 5. Discussion

In our previous prototype the image overlay device was mounted in the inner laser plane of the scanner, the physician's workspace was often restricted and several targets were not accessible [6]. Therefore, the unanimous decision of the participating physicians was to use the outer laser plane of the scanner, even though it required translation of the CT table between imaging and needle insertion. Needle insertion was more accurate in phantoms than in human cadavers, for several reasons. First, the phantom tissue was softer and more homogeneous than human cadavers. Also, in phantoms we used 18 G diamond tip needles that barely deflected during insertion, while in the human cadavers we used 22G beveled needles that had a tendency to deflect in the hard and inhomogeneous tissues. Less experienced users had difficulty in holding the needle in the plane of the laser. Although this presently does not seem to be a clinically significant impediment, we consider applying some form of mechanical constraint to aid the physician with holding the needle in the laser plane.

Although respiration could not be simulated in the passive phantoms and cadavers, the IZI Biopsy Strip fiducials placed on the patient around the insertion point are expected to provide robust real-time indication of any patient motion, in which case the insertion can be halted till the patient's body is correctly re-registered. Alternatively, the fiducials can be used for re-registration of the patient, the same manner as the calibration fixture is registered.

We have encountered several minor issues that could prove to be significant as our efforts are gearing up toward clinical trials. For example, it is inconvenient to have the planning laptop in the scanner room and its wire connection may also disrupt normal traffic. (In the clinical device, the laptop will be situated next to the console and apply wireless communication to the mouse used for calibration. Also, slight changes in backlight and glare on the display frame have also caused difficulties.)

In summary, all needle placement attempts, to both phantoms and cadavers, were technically successful and clinically sufficient needle placement accuracy was confirmed in post-insertion CT imaging. The workflow process and instrumentation have



not been optimized to yield minimum procedure time and the ergonomics of the system still need to improve; these are subjects to current research. Nevertheless, the current embodiment was found to be sufficiently accurate and safe for initial human trials in a plurality of needle placement applications, in which the previously described cadaver studies are predicative of clinical performance. Presently, IRB approval is being sought to commence human trials while software and hardware refinements will continue.

## Acknowledgements

Funding was available from NSF ERC-9731478, Siemens Corporate Research (Princeton, NJ), and Ministry of Education, Science, Sports and Culture, Grant-in-Aid for Young Scientists #14702071. We are grateful to Beatrice Mudge, RTT for her help throughout the experiments and Frank Sauer, PhD (Siemens) for his advice.

## References

1. Sauer F, Khamene A, Vogt S: An Augmented Reality Navigation System with a Single-Camera Tracker: System Design and Needle Biopsy Phantom Trial. *Fifth International Conference on Medical Image Computing and Computer-Assisted Intervention, Lecture Notes in Computer Science 2489*, pp 116-124, Springer, 2002.
2. Birkfellner, W. Figl, M. Huber, K. Watzinger, F. Wanschitz, F. Hummel, J. Hanel, R. Greimel, W. Homolka, P. Ewers, R. Bergmann, H: A head-mounted operating binocular for augmented reality visualization in medicine - design and initial evaluation, *IEEE Transactions on Medical Imaging*, Volume: 21, No. 8, pp 991-7, 2002.
3. Grimson WEL, Lozano-Perez L, Wells WM, Ettinger GJ, White SJ, Kikinis R: An Automatic Registration Method for Frameless Stereotaxy, *Image Guided Surgery, and Enhanced Reality Visualization, IEEE Trans. Med. Imag.* Vol.15, No.2, 1996.
4. Blackwell M, Nikou C, DiGioia AM, Kanade T: An Image Overlay System for Medical Data Visualization, *First International Conference on Medical Image Computing and Computer-Assisted Intervention, Lecture Notes in Computer Science 1496*, pp.232-240, Springer, 1998.
5. Masamune K, Masutani Y, Nakajima S, Sakuma I, Dohi T, Iseki H, Takakura K: Three-dimensional Slice Image Overlay System with Accurate Depth Perception for Surgery, *Third International Conference on Medical Image Computing and Computer-Assisted Intervention, Lecture Notes in Computer Science 1935*, pp.395-402, Springer, 2000.
6. Masamune K, Fichtinger G, Deguet A, Matsuka D, Taylor RH: An Image Overlay System with Enhanced Reality for Percutaneous Therapy Performed Inside CT Scanner, *Fifth International Conference on Medical Image Computing and Computer-Assisted Intervention, Lecture Notes in Computer Science 2488, Part 2*, pp 77-84, Springer, 2002.
7. Stetten G, Chib V: Magnified Real-Time Tomographic Reflection, *Fourth International Conference on Medical Image Computing and Computer-Assisted Intervention, Lecture Notes in Computer Science 2208*, pp.683-690, Springer, 2001.
8. Stetten GD, Cois A, Chang W, Shelton D, Tamburo RJ, Castellucci J, von Ramm O: C-Mode Real Time Tomographic Reflection for a Matrix Array Ultrasound Sonic Flashlight. *Sixth International Conference on Medical Image Computing and Computer-Assisted Intervention, Lecture Notes in Computer Science 2879*, pp 336-343, Springer, 2003.